Psychiatry Research: Neuroimaging 287 (2019) 70–74

Contents lists available at ScienceDirect

Psychiatry Research: Neuroimaging

journal homepage: www.elsevier.com/locate/psychresns

Brain volumes and their ratios in Alzheimer´s disease on magnetic resonance imaging segmented using Freesurfer 6.0

Ales Bartos[a,b,*], David Gregus[a,b], Ibrahim Ibrahim[c], Jaroslav Tintěra[a,c]

[a] National Institute of Mental Health, Topolová 748, Klecany 250 67, Czechia
[b] Charles University, Third Faculty of Medicine, University Hospital Královské Vinohrady, Department of Neurology, AD Center, Šrobárova 50, 100 34 Prague 10, Czechia
[c] Institute of Clinical and Experimental Medicine, Czechia

ARTICLE INFO

Keywords:
Alzheimer's disease
Volumetry
Magnetic resonance imaging
MRI
FreeSurfer
Mild cognitive impairment
Dementia

ABSTRACT

Ratios between opposing volumes from brain magnetic resonance imaging (MRI) can provide additional information to volumes in Alzheimer's disease (AD). Brain three-dimensional MPRAGE MRI at 3T were segmented into 44 regions using FreeSurfer v6 in 75 participants. The region's size in absolute volumes and relative proportions to the whole brain volume were compared between 39 AD patients and 36 age-, education- and sex-matched normal controls (NC). Volumes of the most atrophied parts were related to the opposing volumes of the most enlarged parts as ratios. The most atrophic structures in AD were both hippocampi. By contrast, the greatest enlargements in AD were inferior parts of both lateral ventricles. The best ratio for each side was the hippocampo-horn proportion calculated as ratio: the hippocampus / (the hippocampus + inferior lateral ventricle). Its optimal cut-off of 74% yielded sensitivity of 74% and specificity of 78% on the left and sensitivity of 74% and specificity of 78% on the right. The hippocampo-horn proportion is another measure to evaluate the degree of hippocampal atrophy on brain MRI in percentages. It has a potential to be simplified into a comparison of two-dimensional corresponding areas or a visual assessment.

1. Introduction

Alzheimer´s disease (AD) has different effects on various brain regions. Volumes on magnetic resonance imaging (MRI) can be decreased, increased or unchanged in AD. Predominant AD atrophy is localized in limbic structures involving the hippocampus, entorhinal cortex and amygdala (Apostolova et al., 2012; Basiratnia et al., 2015; Dallaire-Theroux et al., 2017; Geuze et al., 2005b; Giesel et al., 2008; Macdonald et al., 2013; Menendez-Gonzalez et al., 2015; Mrzilkova et al., 2014, 2012; Prestia et al., 2011; Ramos Bernardes da Silva Filho et al., 2017; Shi et al., 2009; Schroder and Pantel, 2016; Teipel et al., 2018; Teipel et al., 2017; Teipel et al., 2006). We found normal volumes in the pons and the cerebellum of AD patients (Mrzilkova et al., 2012) and others found other unchanged structures (caudate nucleus, pallidum) (de Jong et al., 2008; Liu et al., 2010).

Brain atrophy results in enlargement of cerebrospinal fluid compartments. The whole lateral ventricle and especially its temporal horn volume were significantly larger in AD than those in control subjects (Apostolova et al., 2012; Giesel et al., 2006; Macdonald et al., 2013; Persson et al., 2017). Ratios of the temporal horn to the lateral ventricular volumes or areas were also higher in AD patients than in the controls (Conejo Bayon et al., 2014; Giesel et al., 2006; Giesel et al., 2008; Menendez-Gonzalez et al., 2014; Menendez Gonzalez et al., 2016). A decrease of the hippocampal volume and a simultaneous increase in the temporal horn volume was found in AD patients compared to control volunteers using both the manual and the semi-automated approach (Apostolova et al., 2012; Giesel et al., 2008; Macdonald et al., 2013; Persson et al., 2017). Moreover, direct quantification of manual tracing of the hippocampus significantly correlated with indirect measurement of the temporal horn volume using semi-automated measurement (Giesel et al., 2008). Therefore smaller volumes closely coexist with larger volumes in a single AD patient and discriminate AD from non-dementia patients (Persson et al., 2017). These contrasting variables may result in ratios with additional potential to absolute volumes. Precise volumes depend on several factors, e. g. head size, brain volume, age (Shi et al., 2009). Another advantage of a relative

Abbreviations: NC, normal controls; AD, Alzheimer's disease; MRI, Magnetic resonance imaging; NIA-AA, National Institute on Aging Alzheimer's Association; MMSE, Mini Mental State Examination; IKEM, Institute of Clinical and Experimental Medicine; ROC, receiver operating characteristic curve; AUC, and the area under the curve

* Corresponding author at: Department of Cognitive Disorders, National Institute of Mental Health, Topolová 748, Klecany near Prague 250 67, Czech Republic.
E-mail address: ales.bartos@nudz.cz (A. Bartos).

https://doi.org/10.1016/j.pscychresns.2019.01.014
Received 22 August 2018; Received in revised form 21 December 2018; Accepted 21 January 2019
Available online 19 March 2019
0925-4927/ © 2019 Published by Elsevier B.V.

relationship between opposing structures may be a reduction of the influence of other factors.

Brain volumes on MRI can be quantified using manual or automated methods (Giesel et al., 2008; Menendez-Gonzalez et al., 2015; Shen et al., 2010). Manual tracing is a time consuming process, needs anatomic expertise and is performed according to different delineations (Geuze et al., 2005a). Moreover, one or only a few structures are usually feasible to measure (Giesel et al., 2008; Mrzilkova et al., 2012). Many more structures of the whole brain can be simultaneously measured using automated algorithms without rater dependent bias. FreeSurfer is one of software tools freely available for such purpose (Fischl et al., 2002). Its results of hippocampal or ventricular volumes are highly correlated to those from manual tracing (Lehmann et al., 2010; Shen et al., 2010). Later versions of FreeSurfer are more sensitive to identify group differences and corresponded best with the results of gold standard manual volumetric methods (Clerx et al., 2015).

The present work investigated the MRI brain atrophies, enlargements and the volume ratios of brain regions in Alzheimer's disease. In particular, we used an automatic approach for segmenting the brain regions (FreeSurfer) and then we compared volumes between AD patients and healthy controls for finding the smaller and greater volumes in AD. The volume ratios were calculated by considering the smallest and greatest volumes. We assumed that some ratios could provide further information in addition to volumes alone.

2. Participants and methods

2.1. Participants

Brain magnetic resonance imaging (MRI) and the Mini-Mental State Examination (MMSE) were examined in 75 individuals recruited at AD center, Department of Neurology, Charles University, Prague, Czech Republic. We included two groups of participants. The first group of patients was followed with dementia due to Alzheimer disease (AD) according to the National Institute on Aging-Alzheimer's Association (NIA-AA) criteria (McKhann et al., 2011). The second group of normal older controls (NC) with normal MMSE scores 27–30 points using recent Czech norms and cut-offs for mild AD (Bartos and Raisova, 2016) were recruited mainly at Universities of Third Age (educational courses for seniors) or were spouses of the patients. We selected only controls over 70 years so that they were of comparable age with AD patients.

All participants signed an informed consent. The research was approved by the Ethics Committee of Prague Psychiatric Center / National Institute of Mental Health.

2.2. Acquisition of magnetic resonance imaging

Brain MRI were acquired in 3D with scanner model SIEMENS TrioTim and software Syngo MR B13 4VB13A. Magnetic field strength was 3T, voxel size 0.85 * 0.85 * 0.85 mm, slice thickness 0.85 mm, repetition time 2000 ms, echo time 4.73 s, scanning sequence GR/IR, acquisition matrix 320 * 384, flip angle 10°. Participants were imaged at Institute of Clinical and Experimental Medicine (IKEM), Prague, Czech Republic.

2.3. Volumetric analysis

Images were processed using the most recent version of FreeSurfer (v6.0) software which creates virtual 3D reconstruction of human brain stacking slices of MR images in 3D space. Then brain structures were segmented due to different contrasts of brain tissue mapped on Talairach atlas template derived from numerous human brains by creators of the software. Next step was the calculation of volumetric values of different brain structures (Fischl et al., 2002). Further we evaluated 44 regions in absolute volumes and as proportions relative to the whole brain volume (volume of all voxels that are neither background nor brain stem but include vessel, optic chiasm and CSF segmentations).

2.4. Volume ratios

We created ratios between significantly smaller brain volumes in AD as numerators and significantly enlarged volumes in AD as denominators, e.g., left hippocampus / left inferior lateral ventricle.

We also used another ratio on each side between the hippocampus as numerator and the entire volume involving the hippocampus and its surrounding ventricular volume (inferior lateral ventricle) as denominator. This ratio expresses the percentage of the hippocampal volume out of the total volume in this region. It is expressed in percentages and will be referred to as the hippocampo-horn proportion in the following text.

2.4.1. Statistical analysis

Gender distribution between groups was compared using chi-square. We used non-parametric statistics due to non-normal distribution of most data using the Kolmogorov-Smirnov test for normality. Volumes and volume ratios between the groups were compared using the Mann-Whitney test. A measure of effect size for the Mann-Whitney U statistic was calculated using eta-squared $\eta^2 = Z^2/(N-1)$. A Spearman´s coefficient was used for correlations. A receiver operating characteristic curve, i.e., ROC curve, and the area under the curve (AUC) were used to determine the optimal cut-off, sensitivities and specificities of the selected MRI volumes and ratios. In a ROC curve the true positive rate (sensitivity) is plotted in function of the false positive rate (100-specificity) for different cut-off points. Each point on the ROC plot represents a sensitivity/specificity pair corresponding to a particular decision threshold. A test with perfect discrimination (no overlap in the two distributions) has a ROC plot that passes through the upper left corner (100% sensitivity, 100% specificity). Therefore the closer the ROC plot is to the upper left corner, the higher the overall accuracy of the test. When the variable under study cannot distinguish between the two groups, i.e. where there is no difference between the two distributions, the area will be equal to 0.5 (the ROC curve will coincide with the diagonal). When there is a perfect separation of the values of the two groups, i.e. there is no overlapping of the distributions, the area under the ROC curve equals 1 (the ROC curve will reach the upper left corner of the plot). The optimal cut-off was chosen when sensitivity and specificity were well balanced and their sum was maximized. We used the nonparametric method of Delong et al. for the calculation of the standard error of AUC and of the difference between two or more AUCs (DeLong et al., 1988).

Logistic regression was performed with dichotomous diagnoses as dependent variable. Independent variables included hippocampal volumes and hippocampo-horn proportion on each side.

We performed analyses using Statistica and MedCalc software. A level of $p < 0.05$ was considered statistically significant. Significant threshold (p-value) was adjusted for multiple comparisons of 44 regions ($0.05/44 = 0.001$).

3. Results

The AD patients were not different from the NC in terms of age, education and gender distributions (Table 1).

Table 2 shows absolute volumes in mm^3, normalized volumes of the brain structure relative to the whole brain volume in percentages and volume ratios selected for the most different brain structures with opposing changes in AD. Regions other than in the table were not significantly different.

The most atrophic structures in AD patients were the hippocampus and amygdala on both sides. On the contrary, the most enlarged structures in AD patients were the inferior parts of the lateral ventricles on both sides and volumes of ventricles and chorioid plexus. Volumes in

Table 1
Participants´ characteristics and group comparisons.

	Alzheimer´s disease patients	Normal elderly controls	*p* value
Number of participants	39	36	
Age at scan (years)	75 ± 8	75 ± 4 range (70–85 years)	n.s.
Years of education	15 ± 3	15 ± 2	n.s.
Female sex	54%	54%	n.s.
MMSE score (0–30 points)	21 ± 4	29 ± 1	< 0.0001

Age, years of education, and MMSE score are expressed as mean ± standard deviation. MMSE – the Mini-Mental State Examination, n.s. – not significant.

AD patients remained unchanged for several structures: subcortical grey matter (thalamus, putamen, pallidum, caudate, accumbens area), the white matter (corpus callosum, the cerebellum), the fourth ventricle and some others.

The hippocampo-horn proportion is similar for the left and the right side both in the AD group (average 53 vs 56%) and in the NC group (average 77 vs 79%). The areas under the curves (AUC) of ROC analysis for the hippocampal proportion were not different between the right (0.80) and left (0.83) side and are presented in Fig. 1. This figure displays two ROC curves, allowing a visual comparison. The optimal cut-off ≤ 74% yielded the sensitivity of 74% and specificity of 78% on the right and sensitivity of 82% and specificity of 78% on the left. Other AUCs were 0.83 for the left inferior lateral ventricle, 0.78 for the right one, 0.78 for the right hippocampus and 0.81 for the left hippocampus.

In logistic regression, the only hippocampo-horn proportion on the left were found to be a significant variable ($p = 0.01$).

Table 3 shows that the hippocampo-horn proportion or the ratio between the hippocampus and the inferior part of the lateral ventricle on each side have higher effect sizes for discrimination between the AD and NC groups than the hippocampus itself.

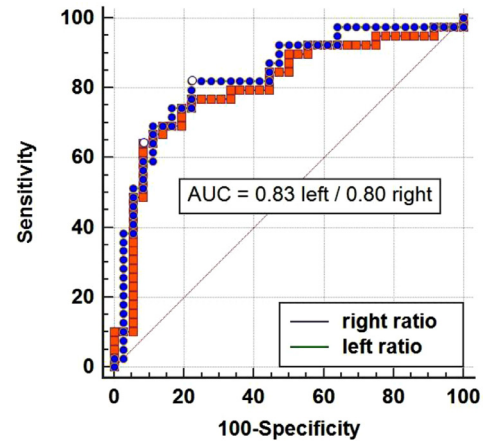

Fig. 1. Receiver operating characteristics curves for the hippocampo-horn proportion of each side between the Alzheimer disease patients and the normal elderly controls. No difference between sides was found.
AUC – area under the curve.

3.1. Influence of sociodemographic variables and correlations

Correlations between sociodemographic variables and brain measures or ratios with significant differences were calculated within the NC group.

Age was significantly correlated with some volumes (the left interior lateral ventricle, the right hippocampus, ventricles and choroid plexus) or ratios (the left hippocampus / inferior lateral ventricle, the hippocampo-horn proportion on the left) (r between 0.35 and 0.45 for absolute volumes and relative proportions).

Years of education did not correlate with any of brain measures except for ratios of right hippocampus / inferior lateral ventricle or the hippocampo-horn proportion ($r = -0.3$).

Differences between men and women were not significant for all

Table 2
Absolute volumes in mm^3, normalized volumes of the brain structure relative to the whole brain volume in percentages and volume ratios selected for the most different brain structures with opposing changes in AD.

Brain structures	Alzheimer disease patients	Normal elderly controls	*p* value	Effect size (eta squared)
Absolute volumes (mm^3)				
Left inferior lateral ventricle	3101.71 ± 3183.66	1058.01 ± 1428.94	0.001069	0.3293
Left hippocampus	2526.84 ± 769.1	3311.13 ± 808.76	0.000002	0.2948
Right hippocampus	2626.34 ± 905.11	3434.93 ± 689.15	0.000000	0.2341
Right inferior lateral ventricle	2747.13 ± 2657.9	1136.22 ± 1813.91	0.000143	0.2329
Right amygdala	1165.5 ± 327.84	1432.4 ± 227.25	0.000031	0.1953
Volume of ventricles and choroid plexus	55,892.23 ± 26,336.72	37,439.41 ± 19,753.7	0.000033	0.1484
Left amygdala	991.53 ± 335.45	1214.23 ± 316.95	0.000919	0.1446
Proportions relative to the whole brain volume (%)				
Left inferior lateral ventricle normalized	0.4 ± 0.53	0.11 ± 0.22	0.001069	0.3378
Left hippocampus normalized	0.26 ± 0.06	0.32 ± 0.06	0.000004	0.2855
Right inferior lateral ventricle normalized	0.35 ± 0.44	0.13 ± 0.28	0.000000	0.2449
Right hippocampus normalized	0.27 ± 0.07	0.34 ± 0.05	0.000439	0.2353
Right amygdala normalized	0.12 ± 0.02	0.14 ± 0.01	0.000317	0.1751
Left lateral ventricle normalized	2.72 ± 1.54	1.66 ± 0.89	0.00003	0.167
Volume of ventricles and choroid plexus normalized	6.43 ± 4.11	3.79 ± 2.07	0.00002	0.1512
Brain segmentation volume without ventricles normalized	92.59 ± 4.97	95.58 ± 2.33	0.00082	0.1446
Ratios				
Left hippocampus/Left inferior lateral ventricle	2.04 ± 2.6	5.24 ± 3.36	0.001069	0.3335
Left hippocampus/(Left inferior lateral ventricle and left hippocampus)	0.53 ± 0.23	0.77 ± 0.15	0.00082	0.3335
Right hippocampus/Right inferior lateral ventricle	3.94 ± 9.62	7.51 ± 6.66	0.000016	0.2764
Right hippocampus/(Right inferior lateral ventricle and right hippocampus)	0.56 ± 0.25	0.79 ± 0.18	0.000421	0.2764
Left amygdala/Left inferior lateral ventricle	0.74 ± 0.83	1.61 ± 1.1	0.000006	0.2097
Right amygdala/Right inferior lateral ventricle	1.46 ± 3.03	2.49 ± 2.28	0,000,000	0.168

Significant threshold (*p*-value) was adjusted for multiple comparisons of 44 regions (0.05/44 = 0.001). Regions other than those in the table were not significantly different.
Smaller brain volumes were used as numerators and greater volumes were used as denominators. Structures or ratios were ranked according to effect sizes using eta squared value between the patients and the controls from the most to the least valuable ones.

Table 3
Effect sizes for relative proportions of the hippocampi and amygdalae and their ratios to ventricle variables between the Alzheimer disease group and the normal control group.

	Hippocampus		Amygdala	
	Left	Right	Left	Right
Absolute volume alone	−0.29	−0.23	−0.14	−0.20
Relative proportions alone	−0.29	−0.24	Na	−0.18
Ratios of the brain structure itself related to:				
Inferior lateral ventricle	**−0.33**	**−0.28**	**−0.21**	−0.17
Hippocampo-horn proportion (Hippocampus / Inferior lateral ventricle + Hippocampus)	**−0.33**	**−0.28**	na	na

The ratios were better than the volume itself. The bold values symbolize better results for the ratios than those for the structure alone. na - not applicable

brain measures including the hippocampo-horn proportion on each side. The right and left hippocampo-horn proportions correlated with each other ($r = 0.7$; $p < 0.0001$). The MMSE scores significantly correlated with all brain measures including the hippocampo-horn proportion and brain ratios on each side in all participants (all r between 0.35 and 0.48).

The hippocampal volumes correlated with those of the inferior lateral ventricle of the corresponding side in all participants (left $r = -0.7$, right $r = -0.7$, $p < 0.000001$)).

4. Discussion

The best ratio on brain MRI for distinguishing the AD patients from the controls is composed of two structures with the greatest opposing changes – hippocampal shrinkage and enlargement of the inferior lateral ventricle. The hippocampal volume is several times greater than the volume of the interior lateral ventricle in the normal controls: eight times on the right and five times on the left. This ratio is reduced in AD patients to four times on the right and twice on the left. This comparison between the two groups was very significantly different with the highest effect sizes as shown in Table 2. The effect sizes of this ratio were higher than those for absolute volumes or relative proportions of the hippocampus itself on both sides as shown in Table 3. By contrast, normalization of the hippocampus to the whole brain volume did not yield better effect sizes at all. Although it seems logical to normalize absolute volumes, our data did not support it. Interestingly, relative and absolute measures segmented using FreeSurfer were comparable regarding volumetric changes between the AD patients and the controls in our study. Volumetric corrections for the hippocampal volumes yielded similar effect sizes compared to those for volumes alone in a meta-analysis (Shi et al., 2009).

Another ratio named the hippocampo-horn proportion provided the exact effect sizes equal to the previous ratio and were greater than those for the hippocampus itself (Table 3). The hippocampo-horn proportion is expressed in percentages. The cutpoint between the two groups for each side is around 75% of magnitude of the hippocampus with reasonable sensitivities and specificities. The advantage of the hippocampo-horn proportion is the relative scale theoretically between 0 and 100%. One could easily imagine the relative reduction of the hippocampus. The range for both groups was between 8% and 98%. The average reduction was 24% (77–53%) for the left hippocampo-horn proportion and 23% (79–56%) for the right side in AD patients compared to the controls. This is surprisingly in exact agreement with figures in large meta-analyses of hippocampal studies (24% on the left, 23% on the right) (Shi et al., 2009).

The right hippocampus is mostly larger than the left hippocampus in normal controls (Shi et al., 2009). If we set the right hippocampo-horn proportion as 100%, the left side was reduced by 3% (56–53%) in the AD patients and by 2% (79–77%) in the normal elderly controls (Table 2). Although the effect size was higher for the left hippocampo-horn proportion than for the right side, we did not observe any side difference in diagnostic performance using AUC comparison between the sides (Fig. 1). This is in agreement with a general view of moreless symmetrical atrophy in AD and supported by other reports in normal elderly using different methods including area measurements (Shen et al., 2010; Zhang et al., 2013).

We confirmed that volumes of the hippocampus and amygdala are the most reduced structures in AD (Apostolova et al., 2012; Geuze et al., 2005b; Giesel et al., 2008; Macdonald et al., 2013; Menendez-Gonzalez et al., 2015; Mrzilkova et al., 2012; Ramos Bernardes da Silva Filho et al., 2017; Shi et al., 2009; Teipel et al., 2018; Teipel et al., 2017; Teipel et al., 2006). Surprisingly, relative proportions as normalization gave similar results to those based on absolute volumes of the hippocampus. Expressions of the hippocampal size are inconsistent. Some reports indicated raw volume, some other studies calculated relative relationships to total intracranial volume or coronal intracranial area (Shi et al., 2009). We offer another indicator using a comparison of two neighboring volumes in percentages. The inferior parts of lateral ventricles were best discriminators across increased volumes of different cerebrospinal fluid compartments.

Strengths of the study include an exact matching for age, sex and education of both groups, MRI acquisition at 3 T with a tiny voxel size 0.85 * 0.85 * 0.85 mm, use of the latest version of FreeSurfer v6 at the time of analysis and a new concept of ratios between smaller and greater volumes. The major advantage of FreeSurfer is the unbiased and uniform segmentation regardless of diagnosis. Human interaction was minimized in the processing using a newer version for FreeSurfer v6. The main advantage of FreeSurfer v6 compared to previous versions was error handling during Talairach registration in reconstruction step. A previous study proved a high correlation and strong agreement between manual and FressSurfer automated determination of hippocampal volumes (Shen et al., 2010). It is also a reliable method for evaluation of the hippocampus or ventricles (Lehmann et al., 2010).

Some limitations in the current study should be mentioned. The group of normal older controls were selected at educational courses for seniors (Universities of Third Age). These individuals can be considered as more active and were more educated than usual general population. Therefore we matched both groups according to the years of education to compensate for this selection bias. The patients with AD were recruited in one site. More centers could include more diverse and heterogeneous group of patients to increase generalizability of our findings. Although we had more brain scans available, their number was reduced due to sociodemographic matching between two groups. We assume that more subjects from the Alzheimer's Disease Neuroimaging Initiative (ADNI) database would provide more confidence and evidence for our outcomes. It would also validate our findings in other population. Furthermore, our patients had mild dementia due to AD. Next investigation should focus on an earlier stage of mild cognitive impairment (MCI). However, our study was explorative to observe whether any ratio exceeds the volume alone. This is an additional explanation of smaller sample size and mild dementia selection. A visual assessment of the ratio is our final goal and can be verified utilizing the ADNI database. It will provide more scans, patients with MCI and other diagnoses.

The hippocampo-horn proportion, defined as the ratio between the hippocampal volume and the sum of the hippocampal volume and the inferior horn of the lateral ventricle, was also used as the hippocampal occupancy score (HOC) for predicting mild cognitive impairment outcome with clinically available MRI. Its discriminative and predictive accuracy exceeds? that of the standard hippocampal volume measure (Heister et al., 2011). Early identification of MCI among men in their 50 s may be supported with HOC as opposed to standard cross-sectional volume (Jak et al., 2015). Thus this particular ratio based on results of our study and others may be a promising MRI biomarker.

Our hippocampo-horn proportion was developed and based on prior

rationale of different volume comparisons. It may be calculated with commercial software packages for brain scan analysis or FreeSurfer software. However, it is still demanding task requiring software and time. Our encouraging results suggest that we might simplify this ratio to a visual assessment. We would like to offer an easy visual assessment based on this ratio for everyday use in clinical practice. It may be used even without software.

5. Conclusion

The hippocampo-horn proportion is another measure to evaluate hippocampal atrophy on brain MRI in percentages. Unlike absolute values which need reference norms, these percentages express the degree of atrophy itself. We are planning to find out whether this outcome based on three-dimensional volumes can be replicated with two-dimensional approach, i.e., a comparison of areas on a selected MRI slice. It could be either manually measured or visually estimated.

Conflict of interest

Authors declare no conflict of interest.

Acknowledgments

This study was supported by institutional support of the Charles University [PROGRES Q 35 and 260388/SVV/2018], Ministry of Health [grant NV18-07-00272], Ministry of Education, Youth and Sports of the Czech Republic [the project “Sustainability for the National Institute of Mental Health”, under grant number LO1611], with a financial support from the National Institute of Mental Health – NIMH [NPU I program and MH CZ - DRO IN: 00023752].

References

Apostolova, L.G., Green, A.E., Babakchanian, S., Hwang, K.S., Chou, Y.Y., Toga, A.W., et al., 2012. Hippocampal atrophy and ventricular enlargement in normal aging, mild cognitive impairment (MCI), and Alzheimer disease. Alzheimer Dis. Assoc. Disord. 26, 17–27.

Bartos, A., Raisova, M., 2016. The Mini-Mental State Examination: Czech norms and cutoffs for mild dementia and mild cognitive impairment due to Alzheimer's disease. Dement. Geriatr. Cognit. Disord. 42, 50–57.

Basiratnia, R., Amini, E., Sharbafchi, M.R., Maracy, M., Barekatain, M., 2015. Hippocampal volume and hippocampal angle (a more practical marker) in mild cognitive impairment: a case-control magnetic resonance imaging study. Adv. Biomed. Res. 4, 192.

Clerx, L., Gronenschild, E.H., Echavarri, C., Verhey, F., Aalten, P., Jacobs, H.I., 2015. Can FreeSurfer compete with manual volumetric measurements in Alzheimer's disease? Curr. Alzheimer Res. 12, 358–367.

Conejo Bayon, F., Maese, J., Fernandez Oliveira, A., Mesas, T., Herrera de la Llave, E., Alvarez Avellon, T., et al., 2014. Feasibility of the medial temporal lobe atrophy index (MTAI) and derived methods for measuring atrophy of the medial temporal lobe. Front. Aging Neurosci. 6, 305.

Dallaire-Theroux, C., Callahan, B.L., Potvin, O., Saikali, S., Duchesne, S., 2017. Radiological-pathological correlation in Alzheimer's disease: systematic review of antemortem magnetic resonance imaging findings. J. Alzheimers Dis. 57, 575–601.

de Jong, L.W., van der Hiele, K., Veer, I.M., Houwing, J.J., Westendorp, R.G., Bollen, E.L., et al., 2008. Strongly reduced volumes of putamen and thalamus in Alzheimer's disease: an MRI study. Brain 131, 3277–3285.

DeLong, E.R., DeLong, D.M., Clarke-Pearson, D.L., 1988. Comparing the areas under two or more correlated receiver operating characteristic curves: a nonparametric approach. Biometrics 44, 837–845.

Fischl, B., Salat, D.H., Busa, E., Albert, M., Dieterich, M., Haselgrove, C., et al., 2002. Whole brain segmentation: automated labeling of neuroanatomical structures in the human brain. Neuron 33, 341–355.

Geuze, E., Vermetten, E., Bremner, J.D., 2005a. MR-based in vivo hippocampal volumetrics: 1. Review of methodologies currently employed. Mol. Psychiatry 10, 147–159.

Geuze, E., Vermetten, E., Bremner, J.D., 2005b. MR-based in vivo hippocampal volumetrics: 2. Findings in neuropsychiatric disorders. Mol. Psychiatry 10, 160–184.

Giesel, F.L., Hahn, H.K., Thomann, P.A., Widjaja, E., Wignall, E., von Tengg-Kobligk, H., et al., 2006. . Temporal horn index and volume of medial temporal lobe atrophy using a new semiautomated method for rapid and precise assessment. AJNR Am. J. Neuroradiol. 27, 1454–1458.

Giesel, F.L., Thomann, P.A., Hahn, H.K., Politi, M., Stieltjes, B., Weber, M.A., et al., 2008. Comparison of manual direct and automated indirect measurement of hippocampus using magnetic resonance imaging. Eur. J. Radiol. 66, 268–273.

Heister, D., Brewer, J.B., Magda, S., Blennow, K., McEvoy, L.K., Alzheimer's Disease Neuroimaging, I., 2011. Predicting MCI outcome with clinically available MRI and CSF biomarkers. Neurology 77, 1619–1628.

Jak, A.J., Panizzon, M.S., Spoon, K.M., Fennema-Notestine, C., Franz, C.E., Thompson, W.K., et al., 2015. Hippocampal atrophy varies by neuropsychologically defined MCI among men in their 50 s. Am. J. Geriatr. Psychiatry 23, 456–465.

Lehmann, M., Douiri, A., Kim, L.G., Modat, M., Chan, D., Ourselin, S., et al., 2010. Atrophy patterns in Alzheimer's disease and semantic dementia: a comparison of FreeSurfer and manual volumetric measurements. Neuroimage 49, 2264–2274.

Liu, Y., Paajanen, T., Zhang, Y., Westman, E., Wahlund, L.O., Simmons, A., et al., 2010. Analysis of regional MRI volumes and thicknesses as predictors of conversion from mild cognitive impairment to Alzheimer's disease. Neurobiol. Aging 31, 1375–1385.

Macdonald, K.E., Bartlett, J.W., Leung, K.K., Ourselin, S., Barnes, J., investigators, A., 2013. The value of hippocampal and temporal horn volumes and rates of change in predicting future conversion to ad. Alzheimer Dis. Assoc. Disord. 27, 168–173.

McKhann, G.M., Knopman, D.S., Chertkow, H., Hyman, B.T., Jack Jr., C.R., Kawas, C.H., et al., 2011. The diagnosis of dementia due to Alzheimer's disease: recommendations from the national institute on aging-Alzheimer's association workgroups on diagnostic guidelines for Alzheimer's disease. Alzheimers Dement. 7, 263–269.

Menendez-Gonzalez, M., de Celis Alonso, B., Salas-Pacheco, J., Arias-Carrion, O., 2015. Structural neuroimaging of the medial temporal lobe in Alzheimer's disease clinical trials. J. Alzheimers Dis. 48, 581–589.

Menendez-Gonzalez, M., Lopez-Muniz, A., Vega, J.A., Salas-Pacheco, J.M., Arias-Carrion, O., 2014. MTA index: a simple 2d-method for assessing atrophy of the medial temporal lobe using clinically available neuroimaging. Front. Aging Neurosci. 6, 23.

Menendez Gonzalez, M., Suarez-Sanmartin, E., Garcia, C., Martinez-Camblor, P., Westman, E., Simmons, A., 2016. Manual planimetry of the medial temporal lobe versus automated volumetry of the hippocampus in the diagnosis of Alzheimer's disease. Cureus 8, e544.

Mrzilkova, J., Koutela, A., Kutova, M., Patzelt, M., Ibrahim, I., Al-Kayssi, D., et al., 2014. Hippocampal spatial position evaluation on MRI for research and clinical practice. PLoS One 9, e115174.

Mrzilkova, J., Zach, P., Bartos, A., Tintera, J., Ripova, D., 2012. Volumetric analysis of the pons, cerebellum and hippocampi in patients with Alzheimer's disease. Dement. Geriatr. Cognit. Disord. 34, 224–234.

Persson, K., Selbaek, G., Braekhus, A., Beyer, M., Barca, M., Engedal, K., 2017. Fully automated structural MRI of the brain in clinical dementia workup. Acta Radiol. 58, 740–747.

Prestia, A., Boccardi, M., Galluzzi, S., Cavedo, E., Adorni, A., Soricelli, A., et al., 2011. Hippocampal and amygdalar volume changes in elderly patients with Alzheimer's disease and schizophrenia. Psychiatry Res. 192, 77–83.

Ramos Bernardes da Silva Filho, S., Oliveira Barbosa, J.H., Rondinoni, C., Dos Santos, A.C., Garrido Salmon, C.E., da Costa Lima, N.K., et al., 2017. Neuro-degeneration profile of Alzheimer's patients: a brain morphometry study. Neuroimage Clin. 15, 15–24.

Shen, L., Saykin, A.J., Kim, S., Firpi, H.A., West, J.D., Risacher, S.L., et al., 2010. Comparison of manual and automated determination of hippocampal volumes in MCI and early ad. Brain Imaging Behav. 4, 86–95.

Shi, F., Liu, B., Zhou, Y., Yu, C., Jiang, T., 2009. Hippocampal volume and asymmetry in mild cognitive impairment and Alzheimer's disease: meta-analyses of MRI studies. Hippocampus 19, 1055–1064.

Schroder, J., Pantel, J., 2016. Neuroimaging of hippocampal atrophy in early recognition of Alzheimer's disease–a critical appraisal after two decades of research. Psychiatry Res. Neuroimaging 247, 71–78.

Teipel, S., Kilimann, I., Thyrian, J.R., Kloppel, S., Hoffmann, W., 2018. Potential role of neuroimaging markers for early diagnosis of dementia in primary care. Curr. Alzheimer Res. 15, 18–27.

Teipel, S.J., Keller, F., Thyrian, J.R., Strohmaier, U., Altiner, A., Hoffmann, W., et al., 2017. Hippocampus and basal forebrain volumetry for dementia and mild cognitive impairment diagnosis: could it be useful in primary care? J. Alzheimers Dis. 55, 1379–1394.

Teipel, S.J., Pruessner, J.C., Faltraco, F., Born, C., Rocha-Unold, M., Evans, A., et al., 2006. Comprehensive dissection of the medial temporal lobe in ad: measurement of hippocampus, amygdala, entorhinal, perirhinal and parahippocampal cortices using MRI. J. Neurol. 253, 794–800.

Zhang, W., Wang, X., Zhou, Z., Li, Y.Q., 2013. A quantitative magnetic resonance study of the hippocampus and the temporal horn of the lateral ventricle in healthy subjects. J. Craniofac. Surg. 24, 1016–1018.